

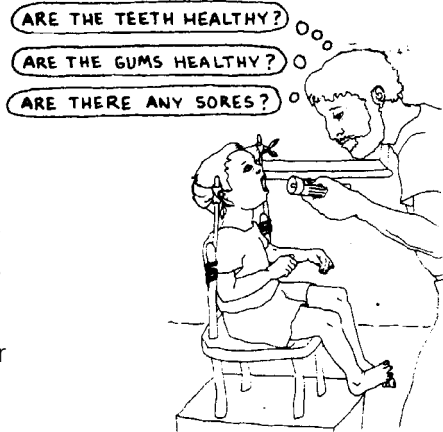
Examination and Diagnosis

Whenever you do an examination, remember to examine the mouth.

You can prevent much suffering and serious sickness when you notice and treat problems early. Whenever you hold a health clinic, try to find out how healthy each person's mouth is.

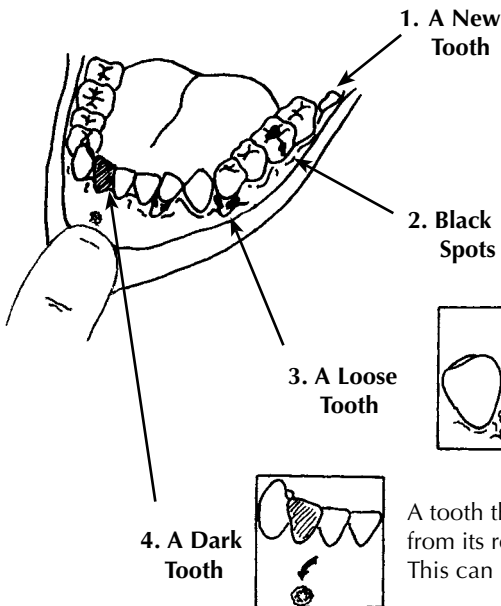
Ask if she is having a problem now, or has had a problem recently.

Always write down what you find out, so you remember what treatment that person needs.

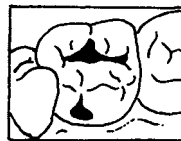

When you look inside someone's mouth, ask yourself these questions.

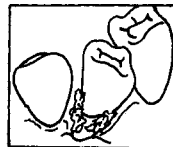
1. Are the teeth healthy? Look for:



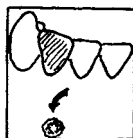
Tell the person what is happening and how to keep the skin around a new tooth healthy (page 66).



They may be cavities which should be filled when they are still small (page 47).



Tell the person what is happening and how to prevent a loose tooth from getting worse or affecting other teeth (pages 54–60).

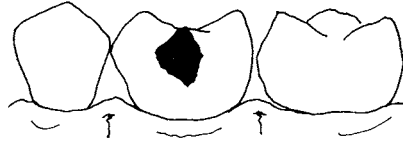


A tooth that is dark is dead and infection from its root can go into the bone (page 47). This can make a sore on the gums (page 74).

2. Are the gums healthy?

Look at page 52 and compare the pictures of healthy and unhealthy gums. **Unhealthy gums often are red and they bleed when you touch them.**

A bubble on the gums below the tooth is a clear sign that the person has an abscess. The abscess may be from the tooth, or it may be from the gums. To decide, look carefully at both the tooth and the gum around it.



A bubble beside a healthy tooth is a sign of infected gums. Scale the tooth carefully. See Chapter 8.



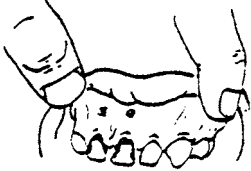

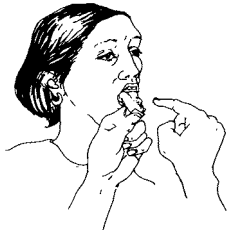
GUM BUBBLE

A bubble beside a decayed tooth is a sign of a tooth abscess. (See page 93.)

A sore on the gums from a badly decayed tooth appears when a gum bubble breaks open and lets out the pus from inside.

3. Are there any sores?

Look for sores under the smooth skin on the inside of the lips and cheeks. Look also under the tongue and along its sides.

 <p>1. A sore on the gums may be from an infected tooth (page 93).</p>	 <p>2. Sores on the inside of the lip or cheek may be from a virus (page 104).</p>	 <p>3. Sores on the lips or tongue may be cancer (page 125).</p>
---	---	---

After your examination, tell the person what you have found. If you notice a problem starting, explain what to do to prevent it from getting worse. If there are no problems and the mouth is healthy, congratulate the person.

**Share your knowledge—explain things to people.
Help them learn how they can prevent and even
manage their own problems with their teeth.**

WHERE TO EXAMINE

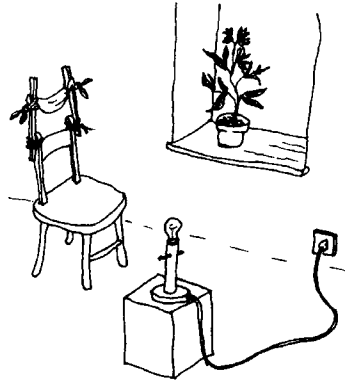
Examine people in a light and bright place. It is dark inside a person's mouth, so you need light to see the teeth and gums.

Use the sun. Examine outside, or inside a room facing the window. With sunlight alone, you will be able to see most places in the mouth well enough. If you cannot, set up a lamp or have someone hold a lamp for you. Reflect the light off a small mouth mirror onto the tooth or gum.

If you have a low chair, lift up the person's chin so that you do not have to bend over as far when you look into the mouth. An even better way is to have the person sit on some books. The person's head can lean back on a piece of cloth.


Use an old chair with a strong back.

Attach two flat sticks to the chair. Then tie a strip of clean cloth to the sticks. Tie it strong enough to support the head, but loose enough to let the head lean back.



THE INSTRUMENTS YOU NEED

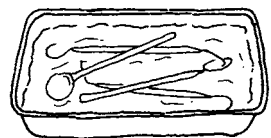
Three instruments are really enough:



1. A wooden tongue blade to hold back the cheek, lips, and tongue.
2. A small mirror to let you look more closely at a tooth and the gums around it.
3. A sharp probe to feel for cavities and to check for tartar under the gum.

If you have many people to examine, it is helpful to have more than one of each instrument. But be sure they are clean.

Dirty instruments easily can pass infection from one person to another. After you finish an examination, clean your instruments in soap and water and then leave them in a germ-killing solution like the ones described on page 89.



A GOOD DIAGNOSIS

You are making a **diagnosis** when you decide what a person's problem is and what is causing it. To do this, you need information. **You need to make a careful examination to make a good diagnosis.**

Learn all you can about the person's problem:

1. Ask questions about the problem.
2. Look at the person's face. Think about the person's age.
3. Examine the mouth more carefully than before.
4. Touch the place that is sore.

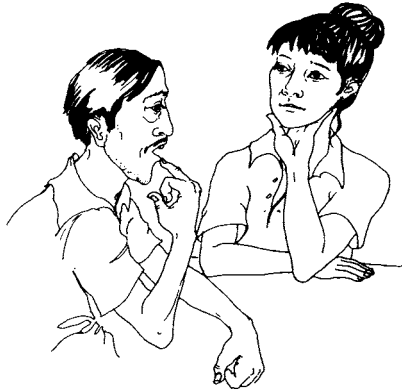1. Ask the person about the problem.

Give a sick person a chance to describe how he is feeling.

Listen. Think about what possibly is happening in his mouth.

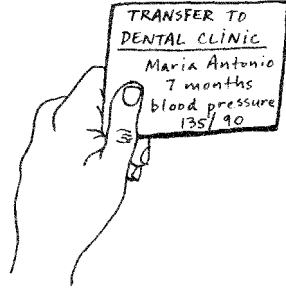
You may have an idea about what the person has. Now try to find out more by asking questions:

- **What is the problem?** Ask him to talk about the pain, swelling, bleeding, or whatever he is feeling.
- **Where does it feel that way?** See if he can put his finger on the tooth or place that is bothering him.
- **When do you have the most pain?** Find out if it happens all the time or only some of the time (for example, when he drinks something very cold).
- **When did it start?** Find out if he has already had this problem before. Ask how he took care of it.
- **Have you had an accident or injury lately?** Infection still inside the bone from an old injury in the mouth can make a sore on his face, or can start swelling.
- **Are you having other problems?** A head cold or fever can make the teeth hurt.
- **How old are you?** Think about a new tooth coming into the mouth.



After you hear the answers to your questions, decide if your original idea is the correct diagnosis. If not, try to think of another possibility and ask more questions. This is the **scientific method** of making a diagnosis. For a good explanation of scientific method, see Chapter 17 of *Helping Health Workers Learn*.

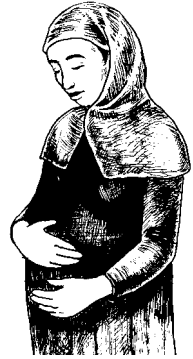When you talk to a woman, find out if she is pregnant. A pregnant woman's gums can easily become infected. The gums may bleed and she may have more tooth decay. But this does not have to happen. If a pregnant woman takes extra care of her teeth and gums, she can prevent most dental problems. But if she already has a problem, do not wait for the baby's birth before you help her. **You can treat a pregnant woman's mouth problems now.** In fact, this may be an important way of protecting her baby as well (see pages 15 to 16).



Train midwives to examine women's mouths. When they send women to you for dental care, they can give you helpful information about the women's health.




Caring for a pregnant woman—a guide for dental workers




1. Ask her how many months she has been pregnant and find out if she has high blood pressure. Any person with blood pressure over 150/100 may bleed excessively after extraction. To get this information, encourage all women to have regular check-ups with a midwife or a trained health worker who has equipment for measuring blood pressure.
2. Do not take X-rays of teeth unless absolutely necessary. X-rays are dangerous to the unborn baby inside. Before an X-ray, always cover the mother's chest, belly, and thighs with an apron lined with lead.
3. Do not give her tetracycline or doxycycline or chloramphenicol while she is pregnant or breastfeeding.
4. Always give a careful and complete mouth examination. Tell her what treatment she needs and how to prevent tooth problems.
5. Be gentle. Show the woman that you care, that you want her to be comfortable, and that you can treat her without hurting her.



2. Look at the person.

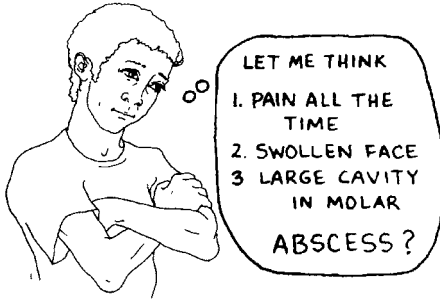
People have some problems more often at certain ages. When a person first comes in to see you, notice his age. Then, before you ask him to open his mouth, look at his face for a sore or swollen area.

SWELLING		
		
CHILD	YOUNG PERSON	ADULT
Swelling can come from:	Swelling can come from:	Swelling can come from:
<ul style="list-style-type: none">• mumps• an infection in the spit gland (page 119)• a tooth abscess (page 93)	<ul style="list-style-type: none">• a new tooth growing in (page 100)• a tooth abscess (page 93)	<ul style="list-style-type: none">• a tooth abscess (page 93)• a broken jaw (page 113)• a tumor (page 125)

A SORE		
		
CHILD	YOUNG PERSON	ADULT
A sore can come from:	A sore can come from:	A sore can come from:
<ul style="list-style-type: none">• impetigo• Vincent's infection (page 102)	<ul style="list-style-type: none">• fever blisters (page 104)• a tooth abscess (page 93)	<ul style="list-style-type: none">• a tooth abscess (page 93)• a bone infection (osteomyelitis)

3. Examine inside the mouth.

Remember what the person said, the person's age, and what you saw. Now look more closely at the problem area.



Look at the teeth:

- Is a new one growing in?
- Is a tooth loose?
- Is there a dark (dead) tooth?

Look at the gums:

- Are they red?
- Is there any swelling?
- Do they bleed?
- Are the gums eaten away between the teeth?

Look also for sores on the inside of the cheek or lips, and on the tongue.

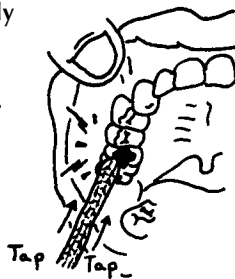
4. Touch the sore place.

Touching is a good way to find out how serious the problem is. This will help you decide which treatment to give.

Push gently against each tooth in the area of pain to see if a tooth is loose. Rock the loose tooth backward and forward between your fingers, to see if it hurts when you move it.

Using the end of your mirror, tap against several teeth, including the one you suspect.

There is probably an abscess on a tooth that hurts when you tap it.

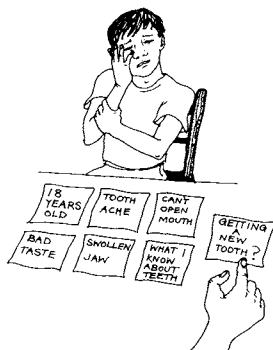

Press against the gums with cotton gauze. Wait a moment, and then look closely to see if they start bleeding. Then use your probe gently to feel under the gum for tartar. Carefully scrape some away. Wait and look again to see if the gums bleed. **When gums bleed, it is a sign of gum disease.**

LEARN TO TELL SIMILAR PROBLEMS APART









If a person comes to you with a toothache or a sore or a loose tooth, there are many possible causes for each problem. The first thing you notice—the toothache, sore or loose tooth—is your first step to a diagnosis. To this you must add more information before you can point to the most probable cause.







Put together what you have found with what you already know about teeth and gums. You can make a good diagnosis of a problem without knowing a special name for it.





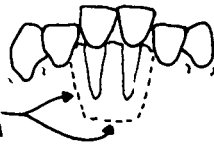
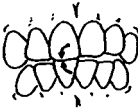







Usually it is easy to make a diagnosis. However, sometimes you will not be sure, and these are the times to seek the advice of a more experienced dental worker. **Never pretend to know something you do not. Only treat problems that you are sure about and have supplies to treat properly.** See *Where There Is No Doctor*, page w4.








Use the charts beginning here to help you make the diagnosis. For more practice using charts to tell problems apart, see Chapter 21 of *Helping Health Workers Learn*.





IF THE PERSON HAS	AND YOU FIND OUT THAT	HE/SHE MAY HAVE	SEE PAGE
<p>A TOOTHACHE</p> 	It hurts only after eating or drinking. There is a cavity, but the tooth does not hurt when you tap it.	 a cavity	92
	Part of the filling has fallen out, or is cracked and ready to fall out. Eating and drinking make the tooth hurt.	 a cavity under an old filling	92
	The tooth hurts when chewing food. It may hurt when tapped, but there is no cavity and the tooth looks healthy.	 tartar between the teeth	129
	It hurts all the time—even when person tries to sleep. The tooth hurts when you tap it and it feels a bit loose.	 an abscess	93
	It hurts when person breathes in cold air. The tooth was hit recently.	 a cracked or broken tooth	96
	He cannot open his mouth properly. Steady pain and a bad taste are coming from the back of the mouth.	 a new tooth growing in	100
	Several top teeth hurt, even more when you tap them. She had a head cold and can only breathe through her mouth.	 an infected sinus	95






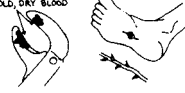
IF THE PERSON HAS	AND YOU FIND OUT THAT	HE/SHE MAY HAVE	SEE PAGE
<p>A SWOLLEN FACE</p> 	<p>He had a toothache recently. The bad tooth hurts when you tap it.</p>	<p>a tooth abscess</p> 	<p>93</p>
	<p>She is young, about 18 years old, and has trouble opening her mouth.</p>		<p>100</p>
	<p>He was hit on the face or jaw. The bone hurts when you touch it. The teeth do not fit together properly.</p>		<p>108</p>
	<p>The swelling is under or behind the jaw. It gets worse when he is hungry and smells food.</p>		<p>119</p>
	<p>The swelling has been there for a long time. It does not seem to get better.</p>		<p>125</p>




<p>A LOOSE TOOTH</p> 	<p>Food and tartar are attached to the tooth. The gums around it are loose and swollen.</p>	<p>infection inside the root fibers—from gum disease</p> 	<p>101</p>
	<p>There was pain in the tooth before, but it does not hurt so much anymore. It has a cavity and there may be a sore on the gums near it.</p>		<p>99 and 93</p>
	<p>The tooth was hit some time ago.</p>		<p>96</p>
	<p>When the loose tooth moves, the bone around it and the tooth beside it also move.</p>	<p>a broken bone around the tooth's roots OR infection inside the bone from Vincent's Infection</p>  <p>BONE BROKEN UNDER THE GUM</p>	<p>108 to 112 102 and 121</p>
	<p>When you ask the person to slowly close his teeth, one tooth hits another, before the other teeth come together.</p>		<p>99</p>

IF THE PERSON HAS	AND YOU FIND OUT THAT	HE/SHE MAY HAVE	SEE PAGE
<p>A SORE MOUTH from INFECTED GUMS</p> 	<p>The gums are red and swollen. They bleed when the teeth are cleaned.</p>		<p>gum disease starting</p> <p>101</p>
	<p>Between two teeth the gums are sore and swollen, like a small tumor.</p>		<p>something caught under the gum</p> <p>133</p>
	<p>The gums between the teeth have died and are no longer pointed. Pus and blood around the teeth make the mouth smell bad.</p>		<p>Vincent's Infection (a more serious gum infection)</p> <p>102</p>
	<p>The gums are bright red and sore, but between the teeth they are still pointed.</p>		<p>fever blisters on the gums— from Herpes Virus</p> <p>104</p>

<p>or A SORE MOUTH from a SMALL SORE in another place</p> 	<p>A sore on the inside of the cheek, lips, or under the tongue, is yellow with the skin around it bright red. Food touching it makes the sore hurt more.</p>		<p>a canker sore</p> <p>106</p>
	<p>A sore spot around or under a denture hurts when you touch it.</p>		<p>a sharp place on a denture, or an old denture that needs to be refitted</p> <p>106</p>
	<p>A kind of white cloth seems to be stuck to the top of the mouth or tongue. It may stop a baby from sucking.</p>		<p>thrush</p> <p>105</p>
	<p>The sore is near the root of a bad tooth.</p>		<p>gum bubble</p> <p>74 and 93</p>
	<p>The corners of the mouth are dry. The lips crack and are sore.</p>		<p>malnutrition</p> <p>107</p>
	<p>Small painful blisters on the lips soon break and form dry scabs.</p>		<p>fever blisters— from Herpes Virus</p> <p>104</p>
	<p>A SORE THAT DOES NOT HEAL PROPERLY MAY BE CANCER (see page 125).</p>		

IF THE PERSON HAS	AND YOU FIND OUT THAT	HE/SHE MAY HAVE	SEE PAGE
<p style="text-align: center;">▼</p> <p style="text-align: center;">A SORE ON THE FACE</p> 	<p style="text-align: center;">▼</p> <p>Inside his mouth, he has a tooth abscess or a broken tooth near the sore.</p> 	<p style="text-align: center;">▼</p> <p>abscessed tooth draining pus to the outside of the face</p>	<p style="text-align: center;">▼</p> <p>120</p>
	<p>A dark sore is eating through the cheek. Her gums are badly infected. A bad smell is coming from the dying skin on the face, and from inside the mouth.</p> 	<p>a condition called <i>Noma</i>—starting from Vincent's Infection of the gums</p>	<p>121</p>
	<p>A 1-month-old sore on the lips is not healing with medicine.</p> 	<p>cancer</p>	<p>125</p>

<p style="text-align: center;">TROUBLE OPENING THE MOUTH</p>  <p style="text-align: center;">I CAN NOT OPEN ANY MORE THAN THIS.</p>	<p>He is young, between 16–24 years, with some swelling behind his jaw.</p>		<p>a new tooth growing in</p>	<p>100</p>
	<p>He recently had an accident.</p>		<p>a broken jaw—probably in front of the ear</p>	<p>108</p>
	<p>He had a toothache before in a back tooth with some swelling.</p>		<p>an abscess in a back tooth</p>	<p>93</p>
	<p>When she tries to open her mouth, there is a clicking sound from in front of her ear. It also hurts in that place whenever she tries to open her mouth or chew food.</p>		<p>pain in the joint—where the jawbone joins the head</p>	<p>114</p>
	<p>Swallowing is difficult and the jaw grows stiff. Germs have gone into the body from dirty instruments or an infected wound.</p>	<p>OLD, DRY BLOOD</p> 	<p>tetanus</p>	<p>118</p>

<p style="text-align: center;">TROUBLE CLOSING THE MOUTH</p> 	<p>After opening wide to eat or yawn, his mouth became stuck there. He has many missing back teeth.</p>		<p>a dislocated jaw</p>	<p>113</p>
	<p>He had an accident and now something is stopping the teeth from coming together.</p>		<p>a broken jaw</p>	<p>108</p>